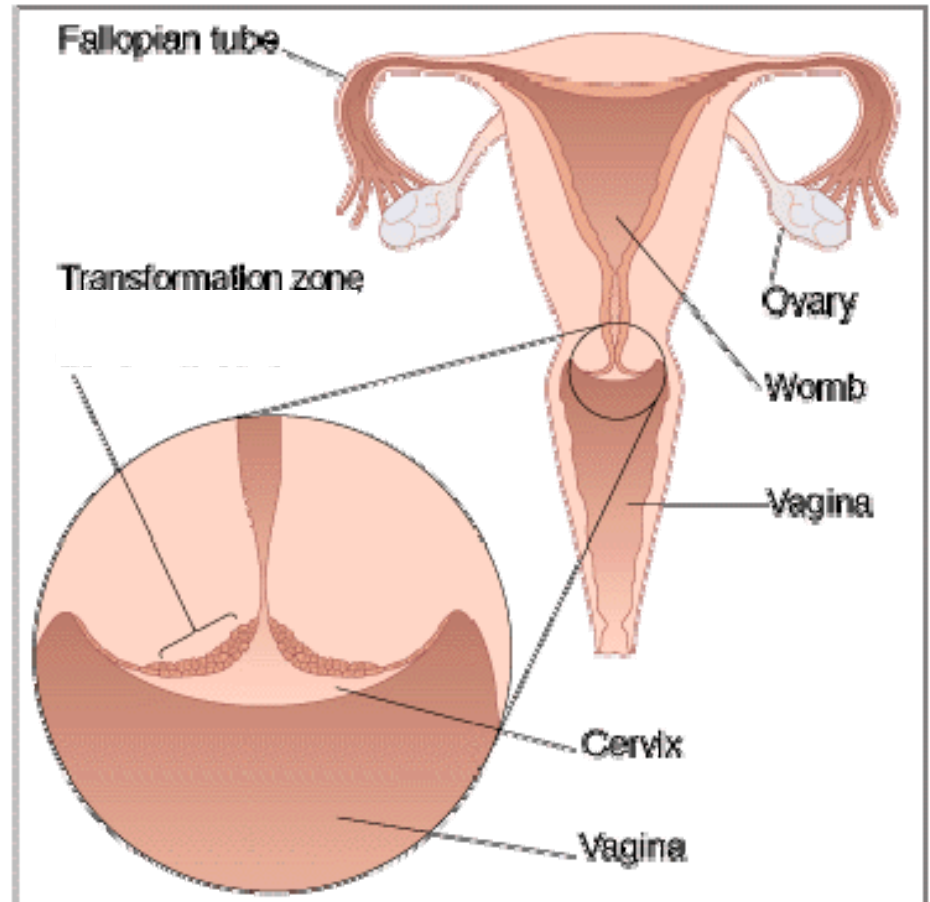
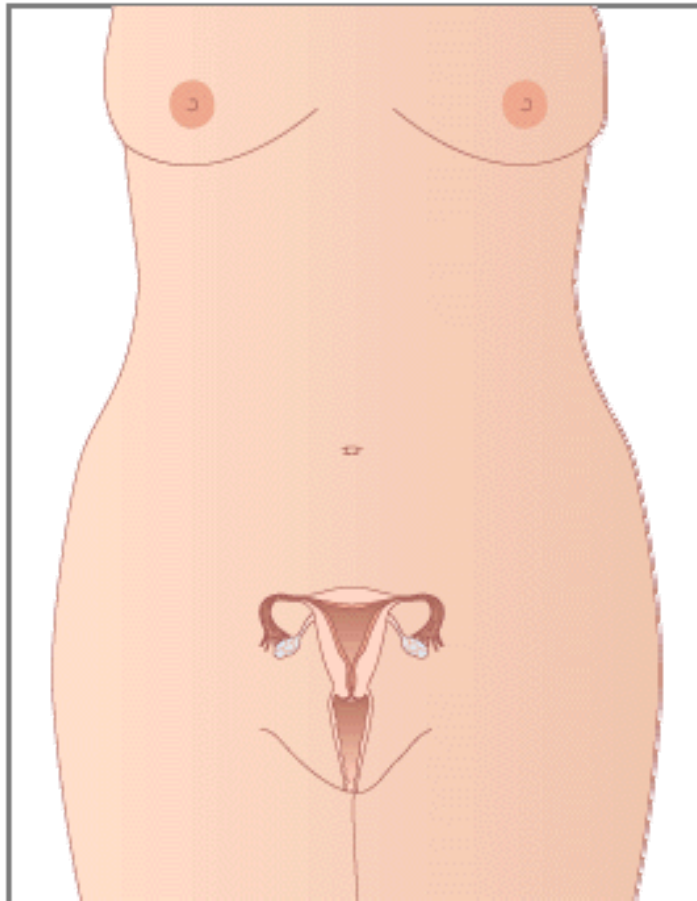


Aspect van de cervix

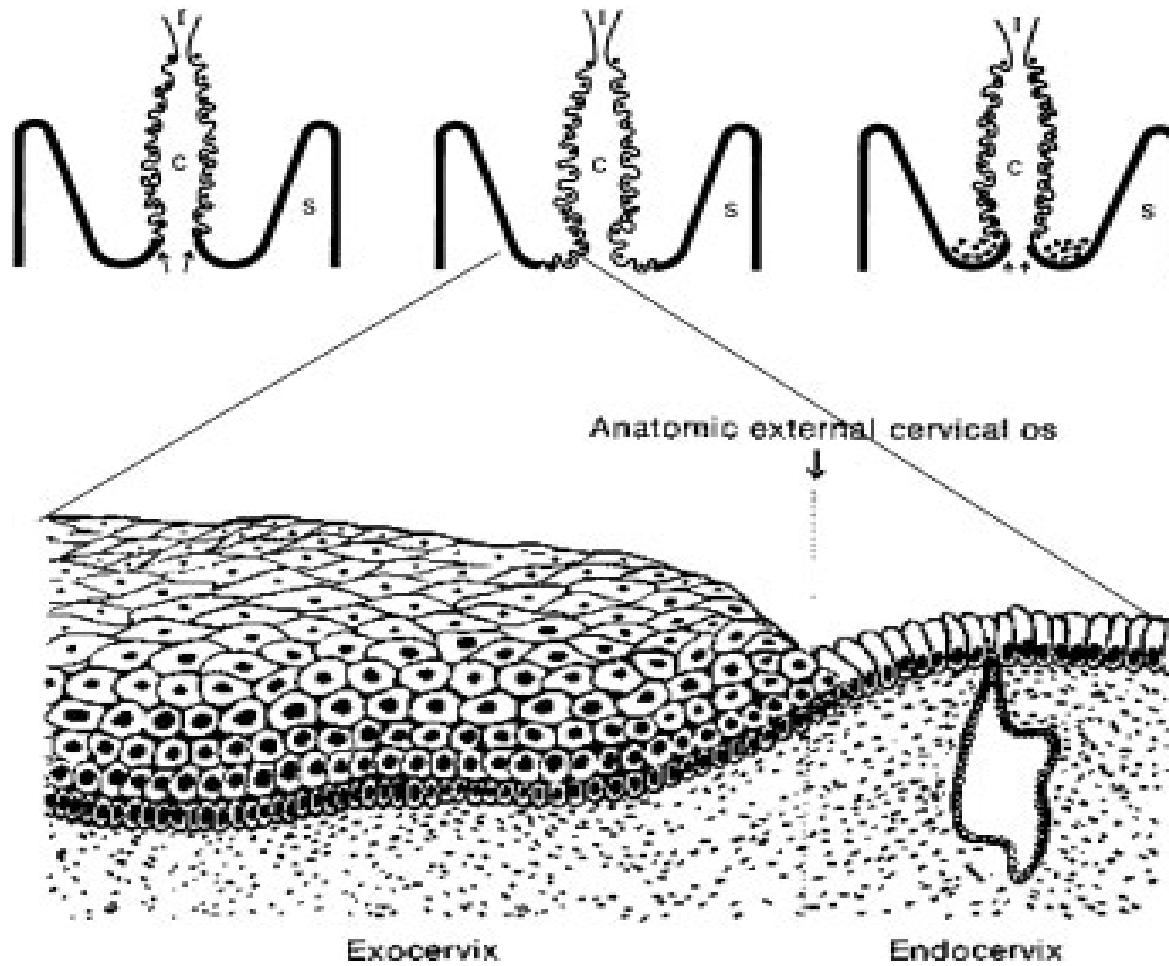
Ruud Bekkers

Gynaecologisch oncoloog
UMC St Radboud Nijmegen

Normale portio

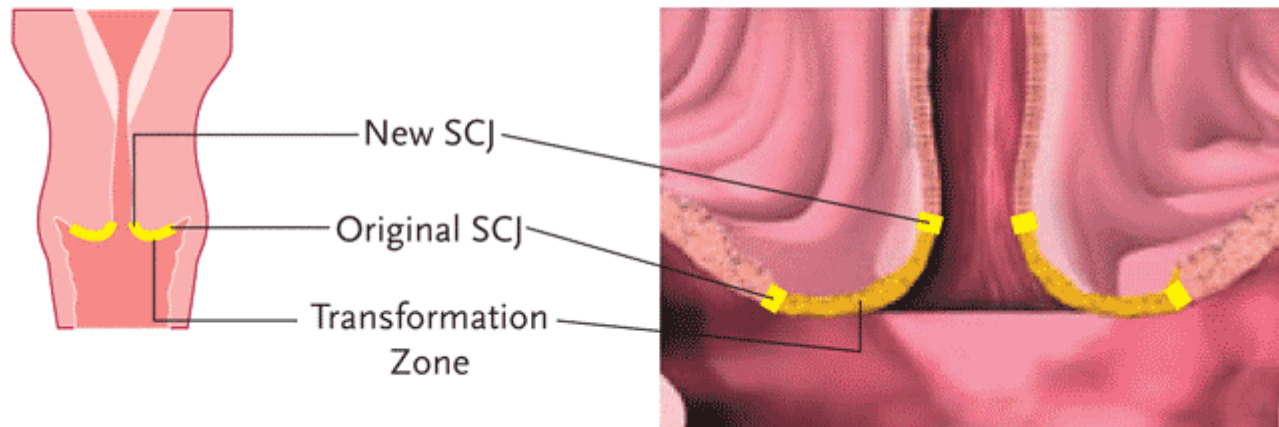


Normale portio



Normale portio

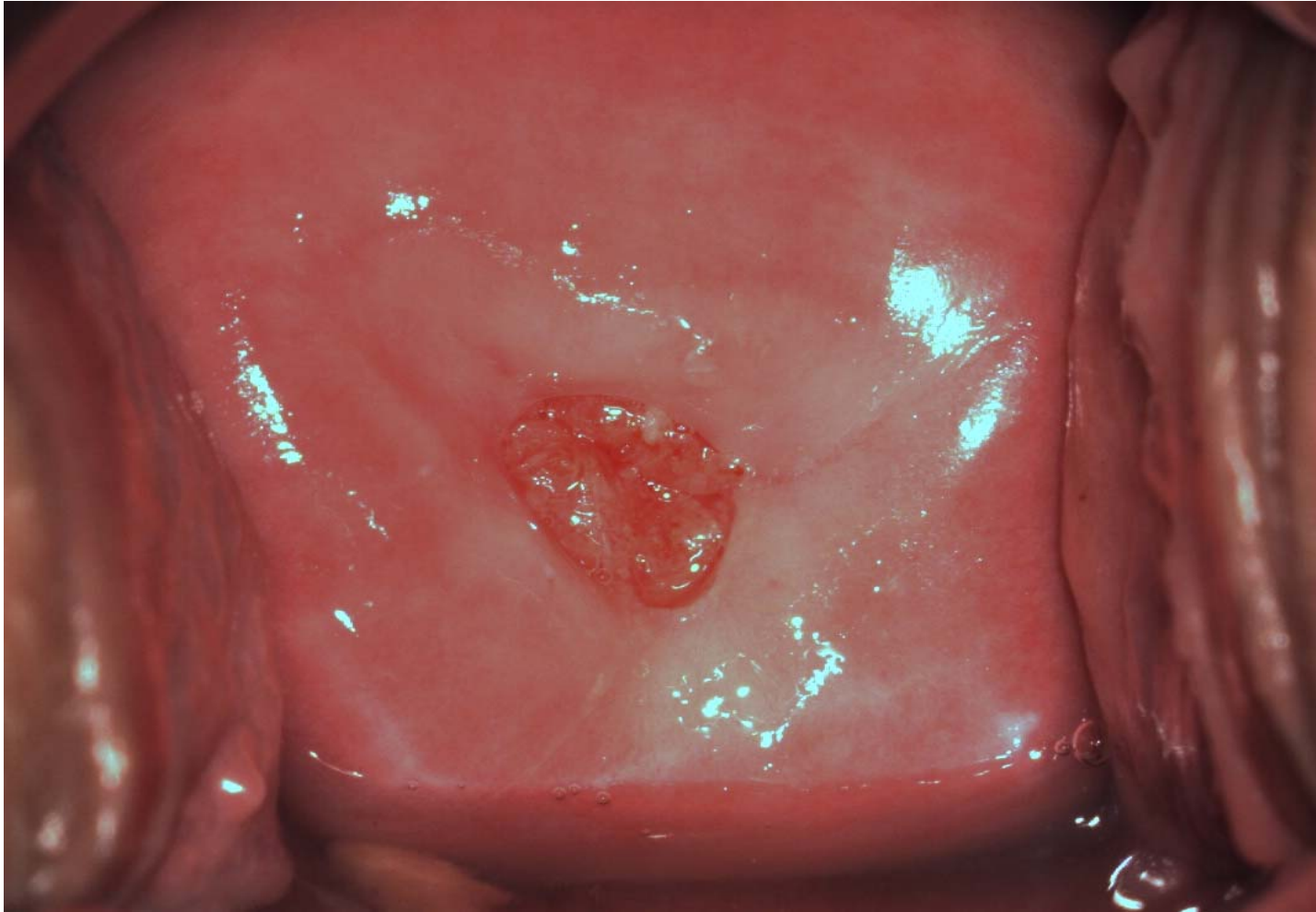
Mid-later Reproductive Stage (30s age-range)



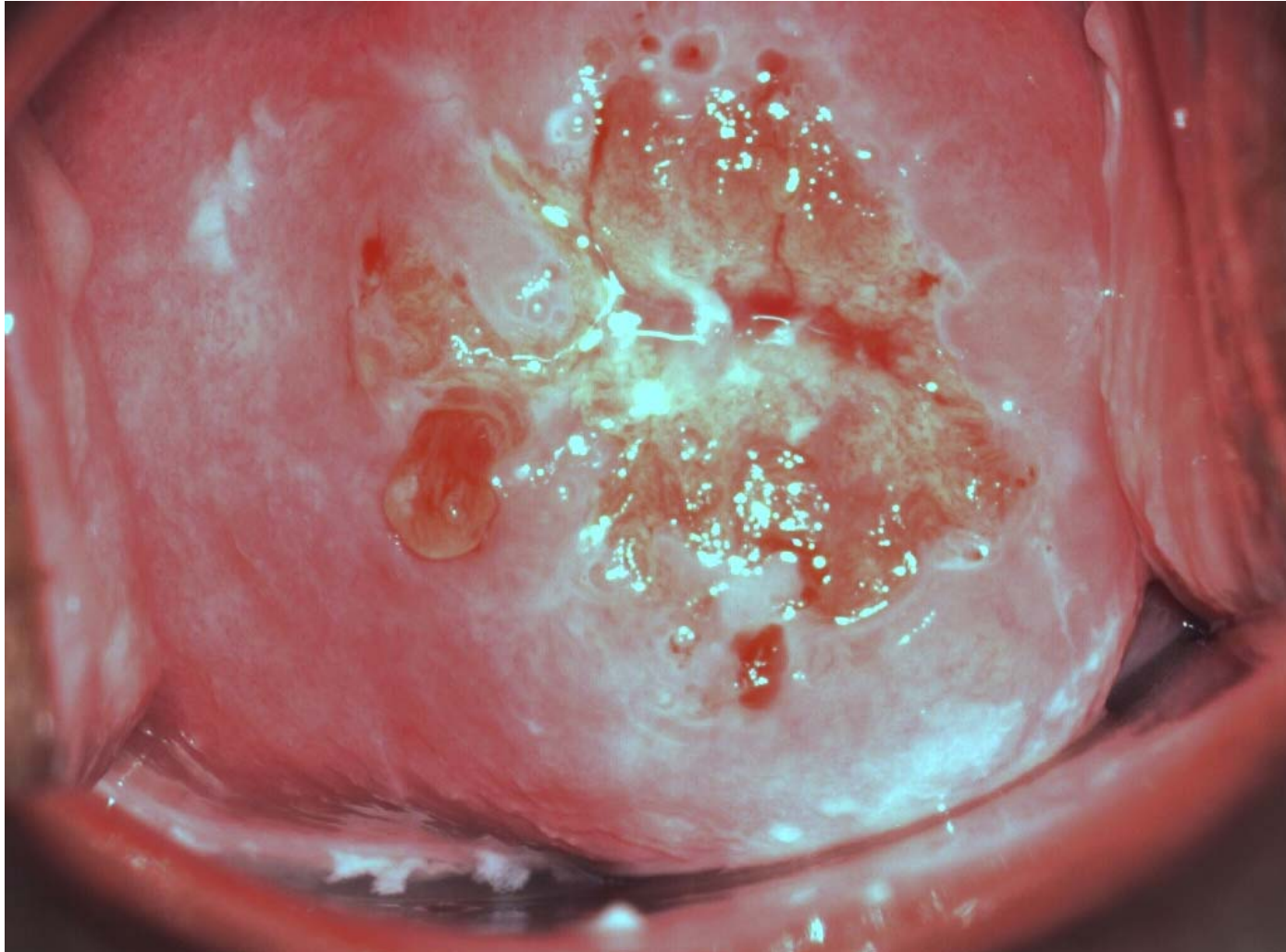
Normale portio

- ***Een portio is voor het maken van een uitstrijkje normaal als:***
 - ***De portio in de vagina uitsteekt***
 - ***de opening van het baarmoederhalskanaal daarin te herkennen is***
 - ***en er met het borsteltje van de uitstrijk in een goede cirkelbeweging een uitstrijkje van de hele baarmoedermond te maken is.***

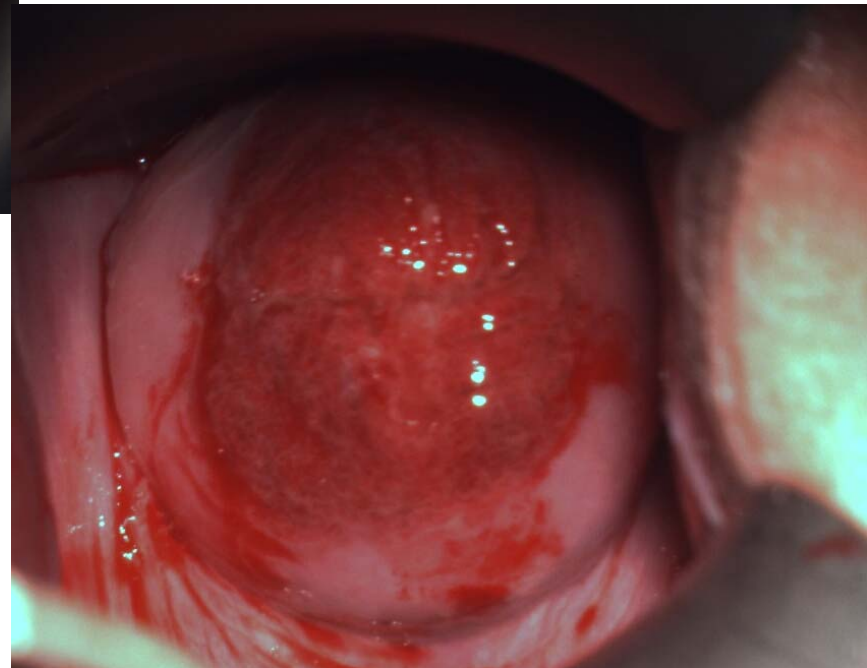
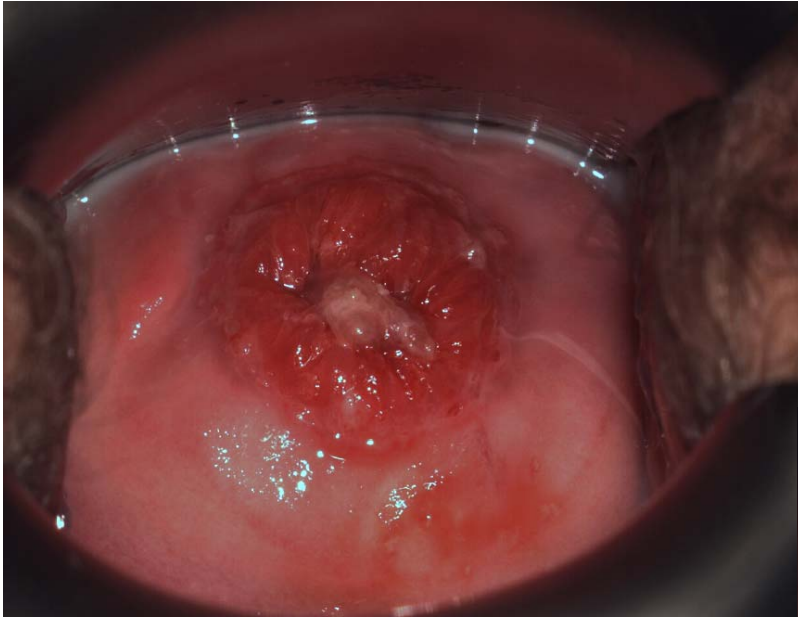
Normale portio?



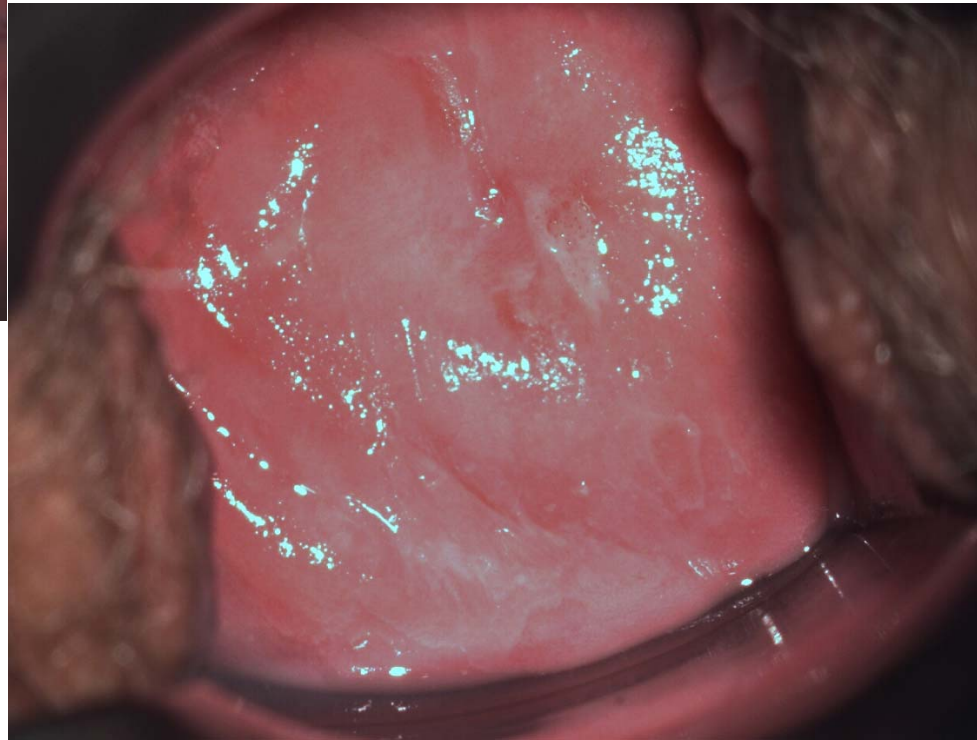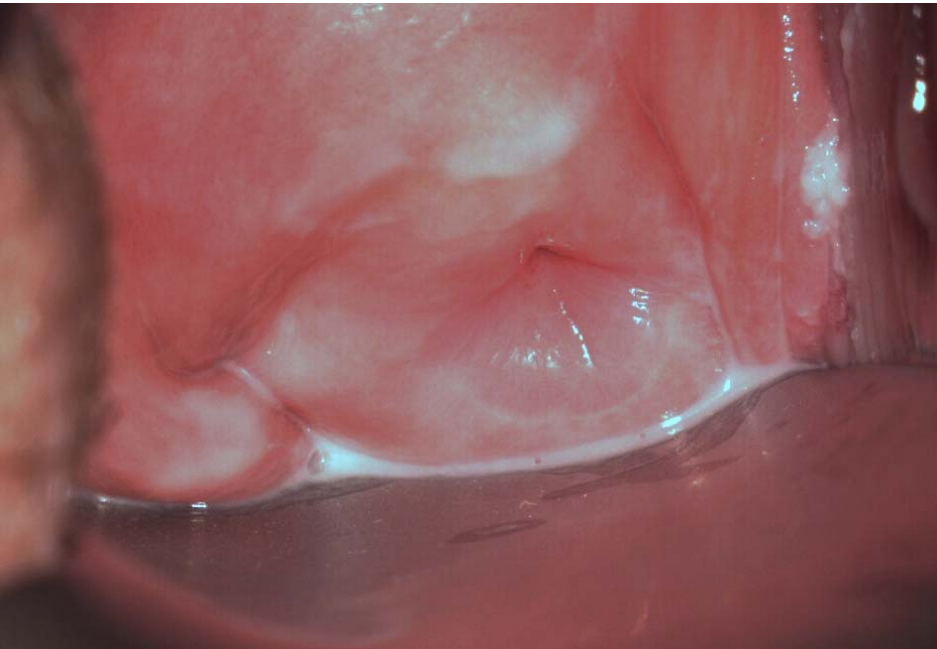
Normale portio?



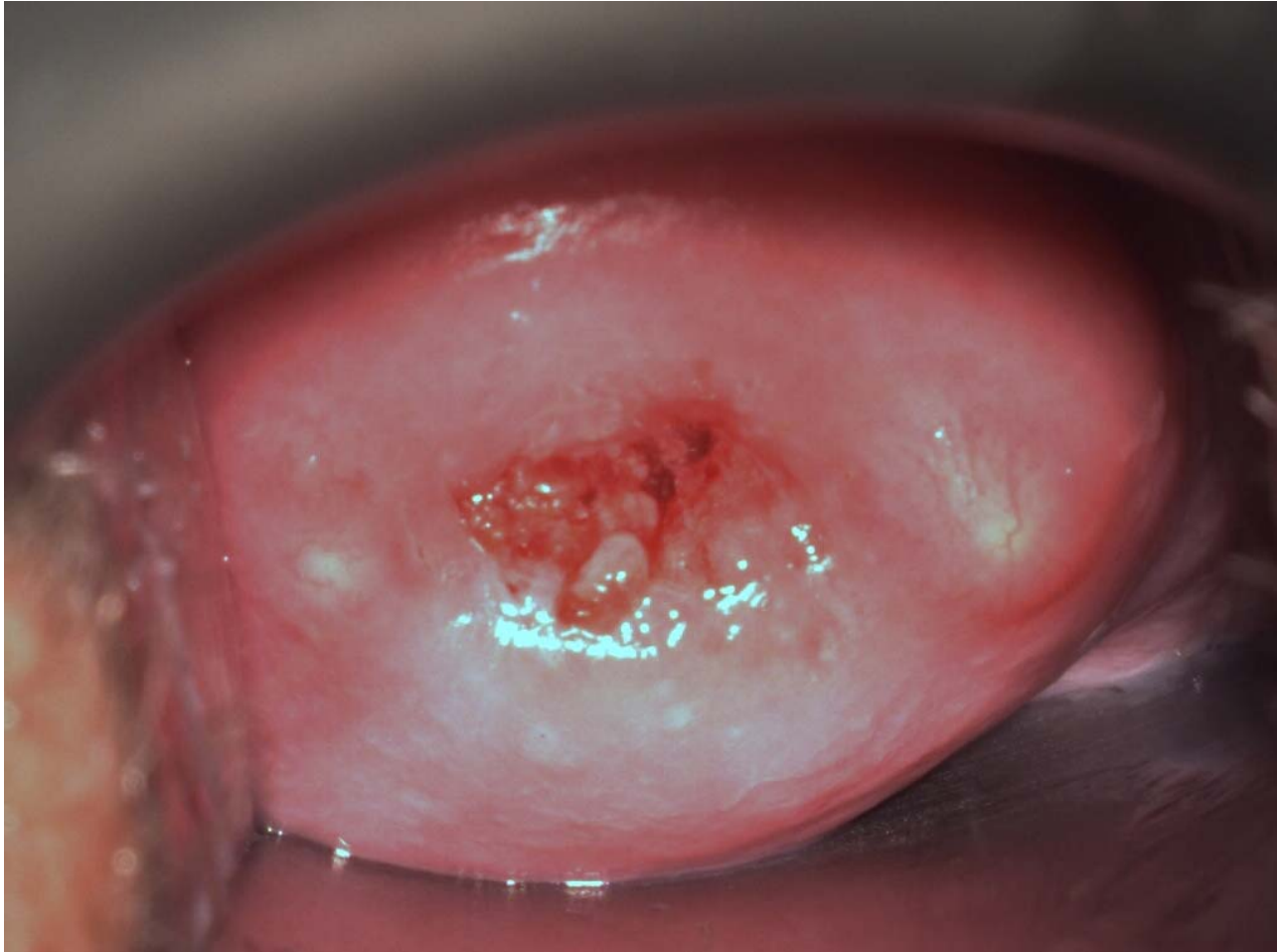
Normale portio?



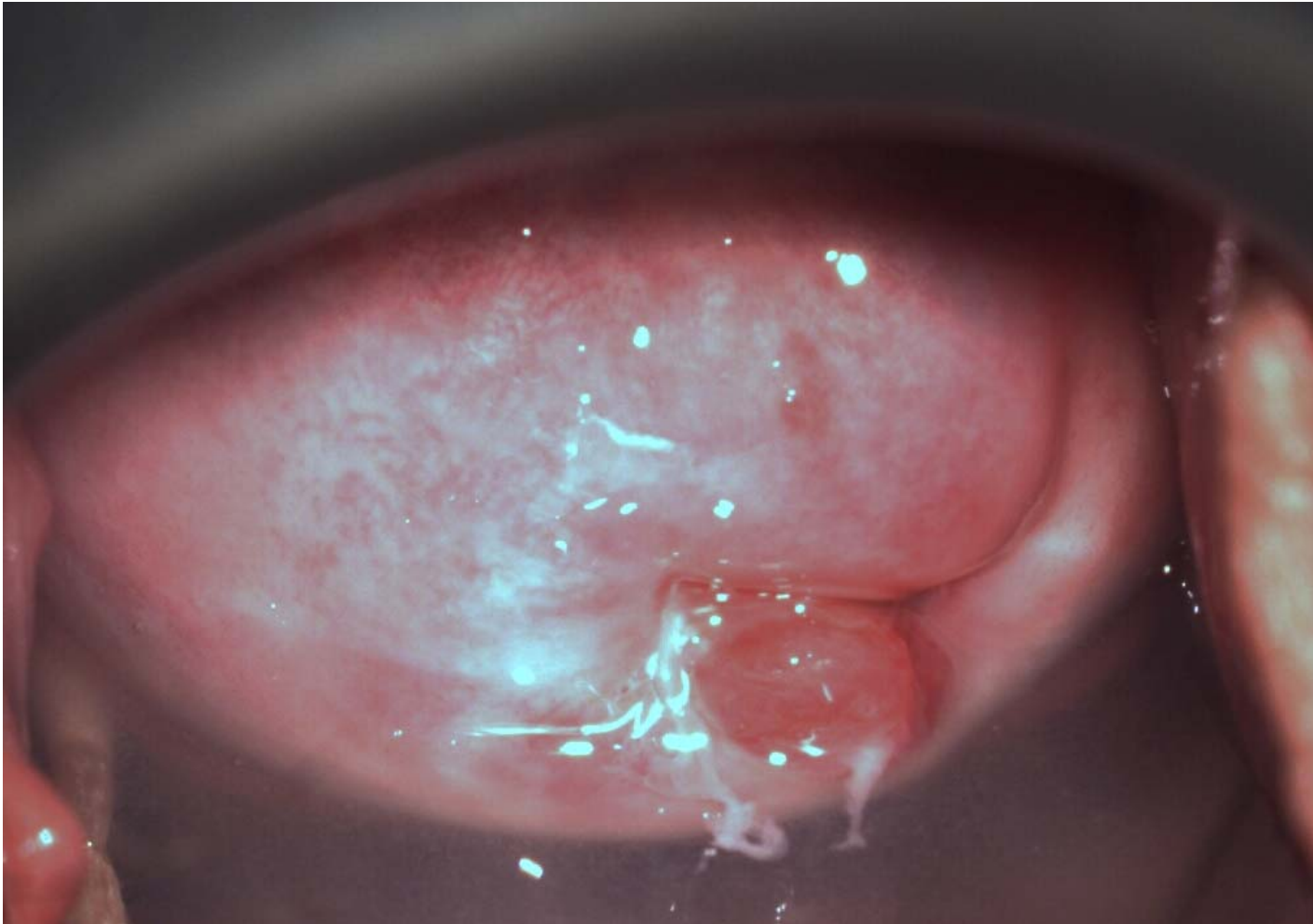
Normale portio?



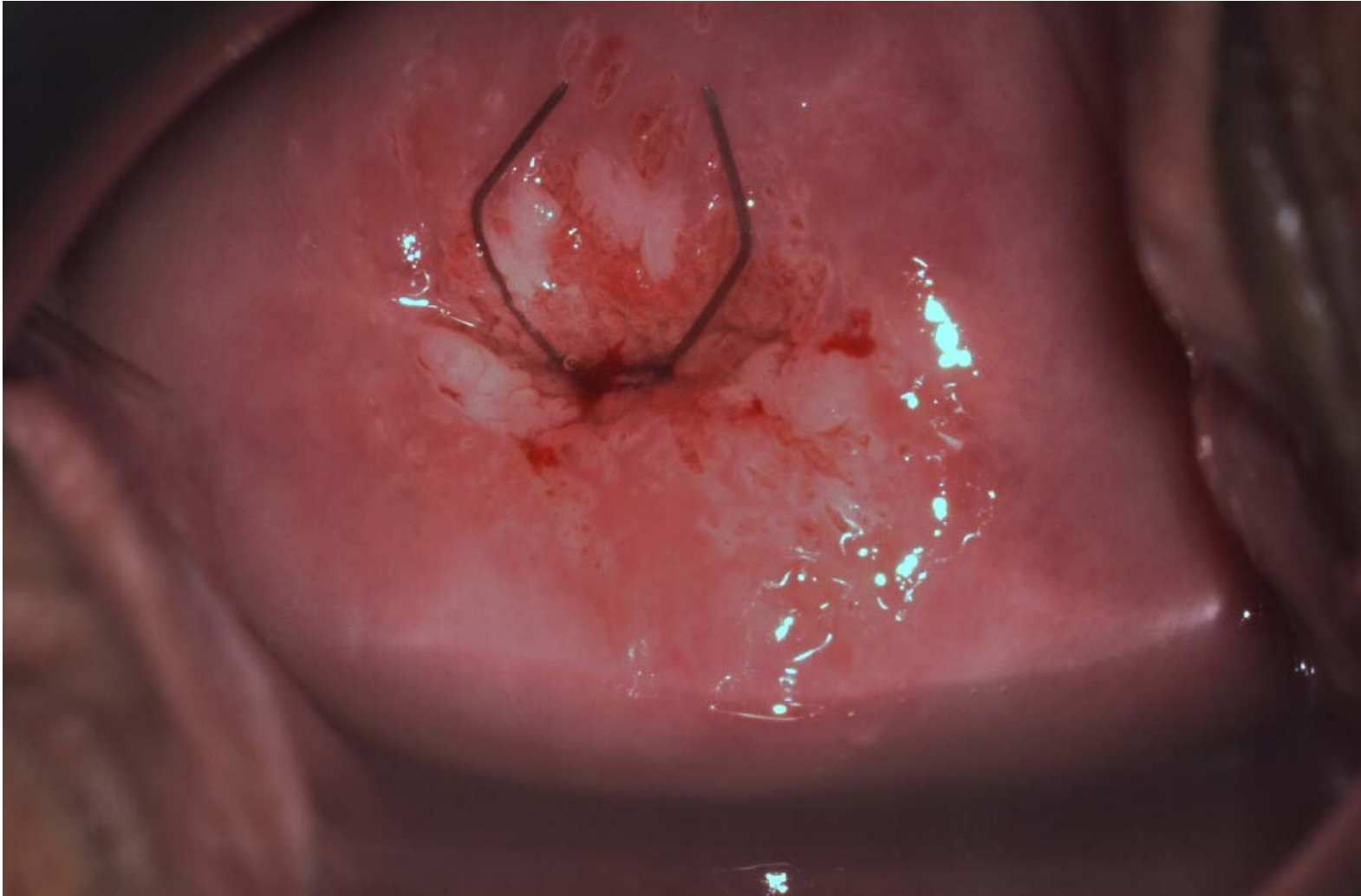
Normale portio ?



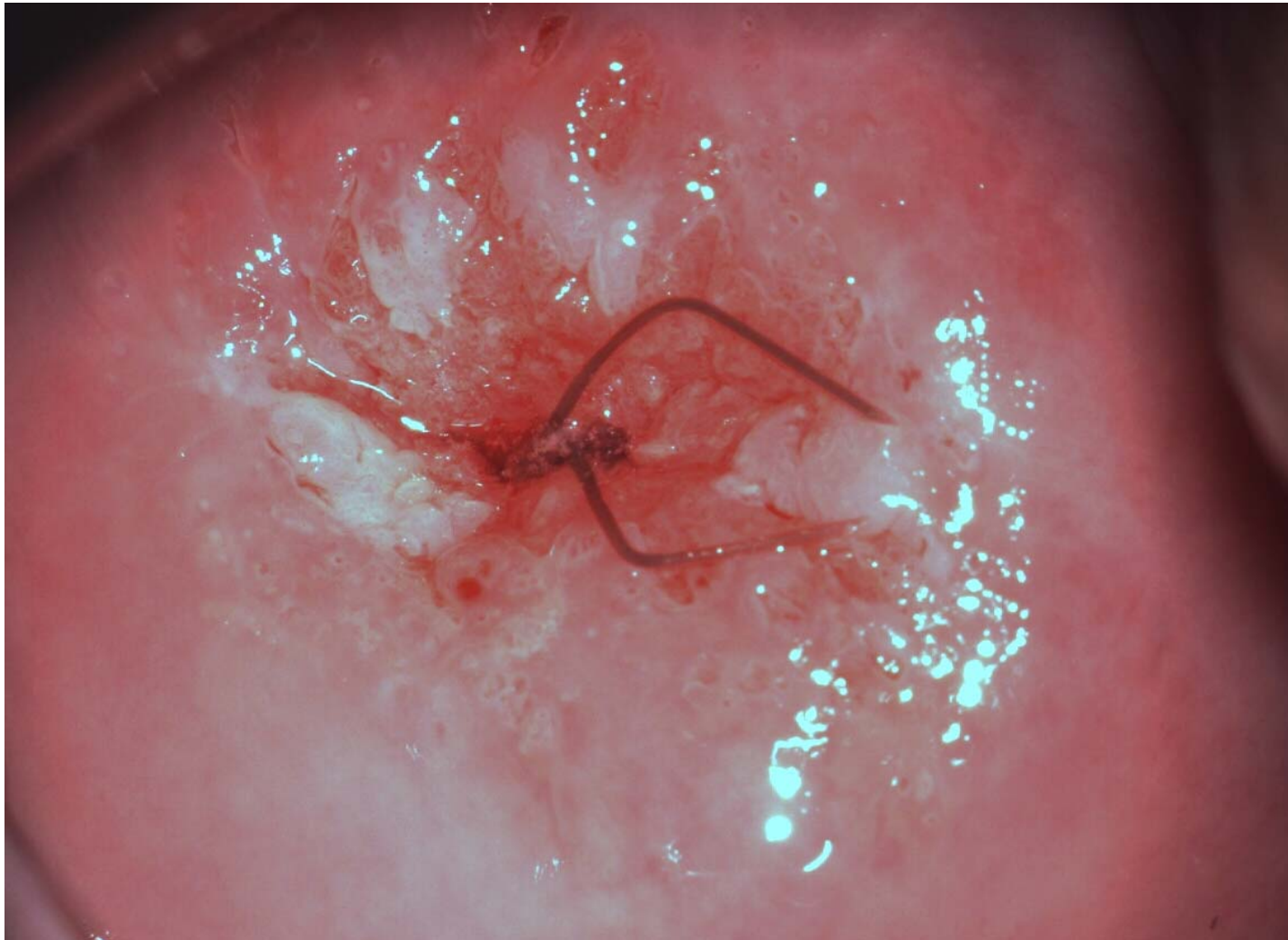
Normale portio ?



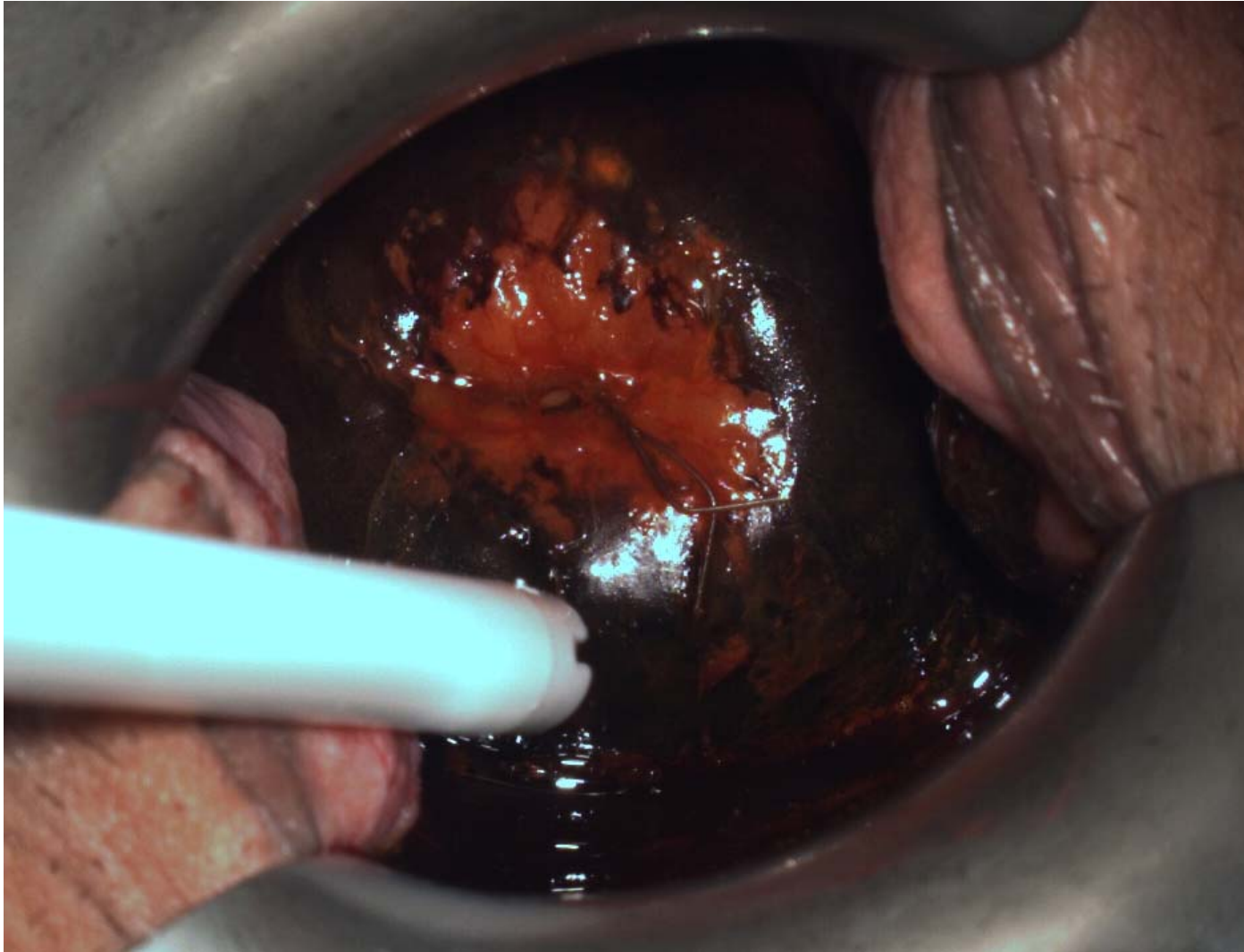Normale portio ?



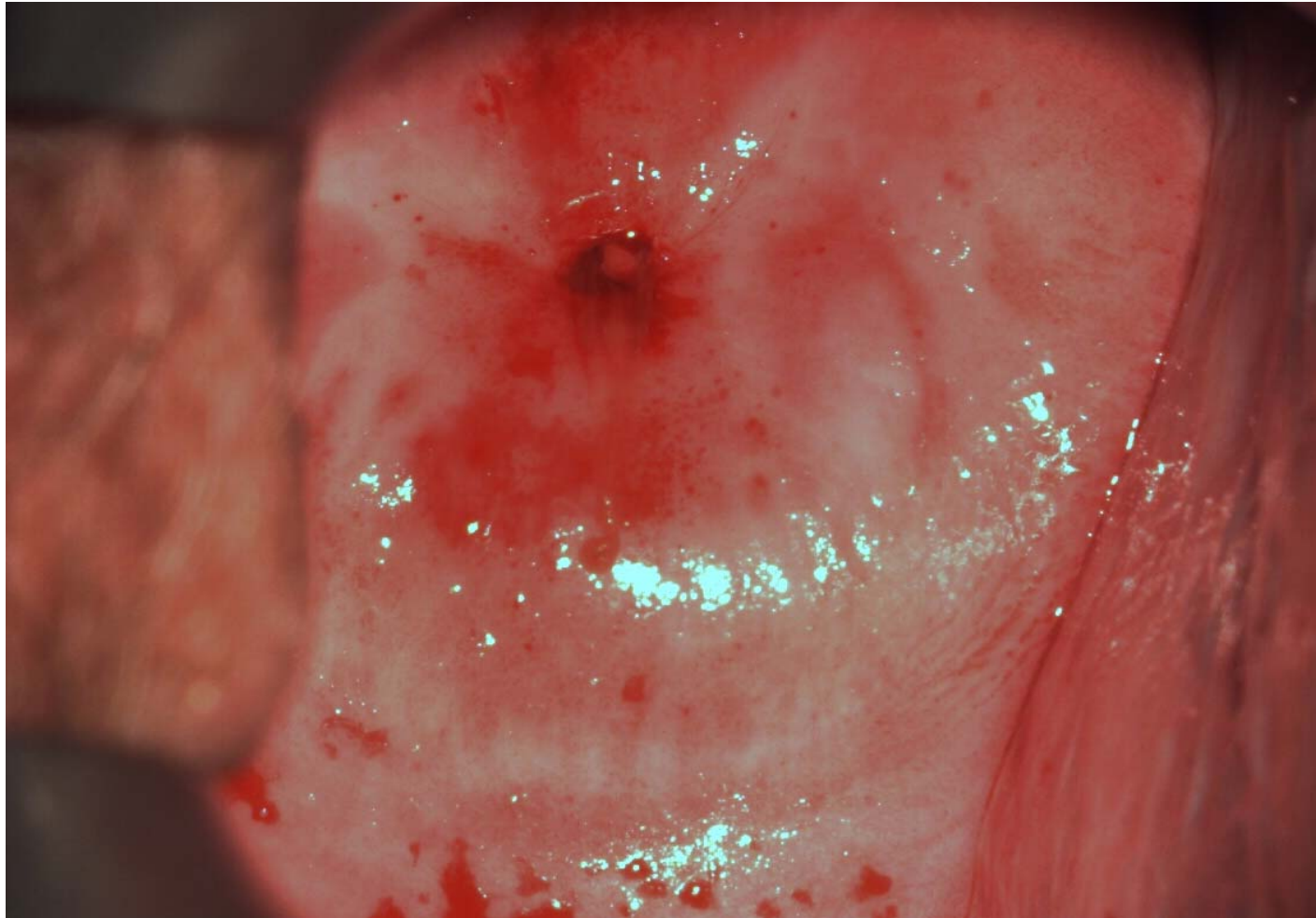CIN 3, azijnzuur



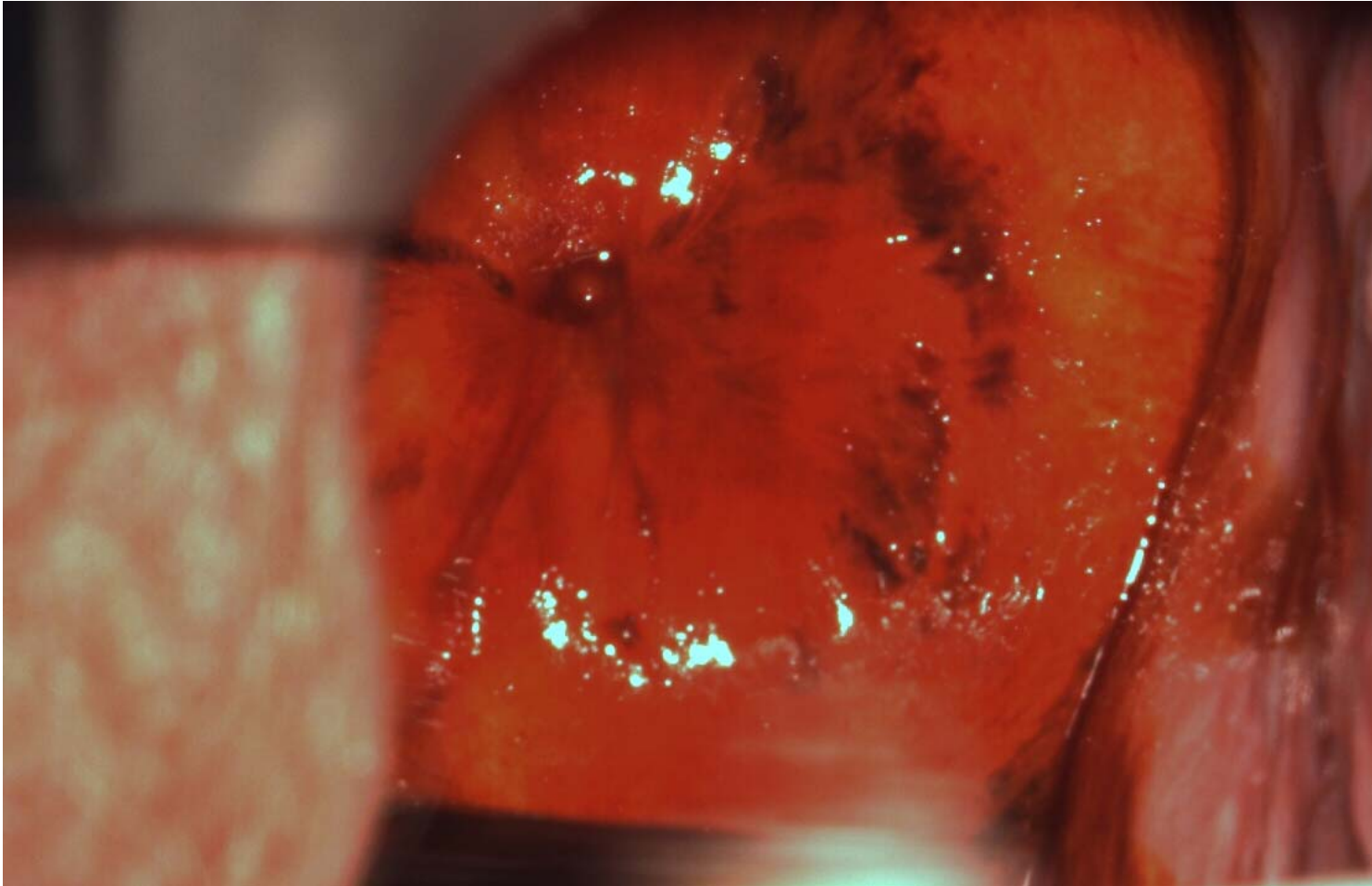
CIN 3 Lugol



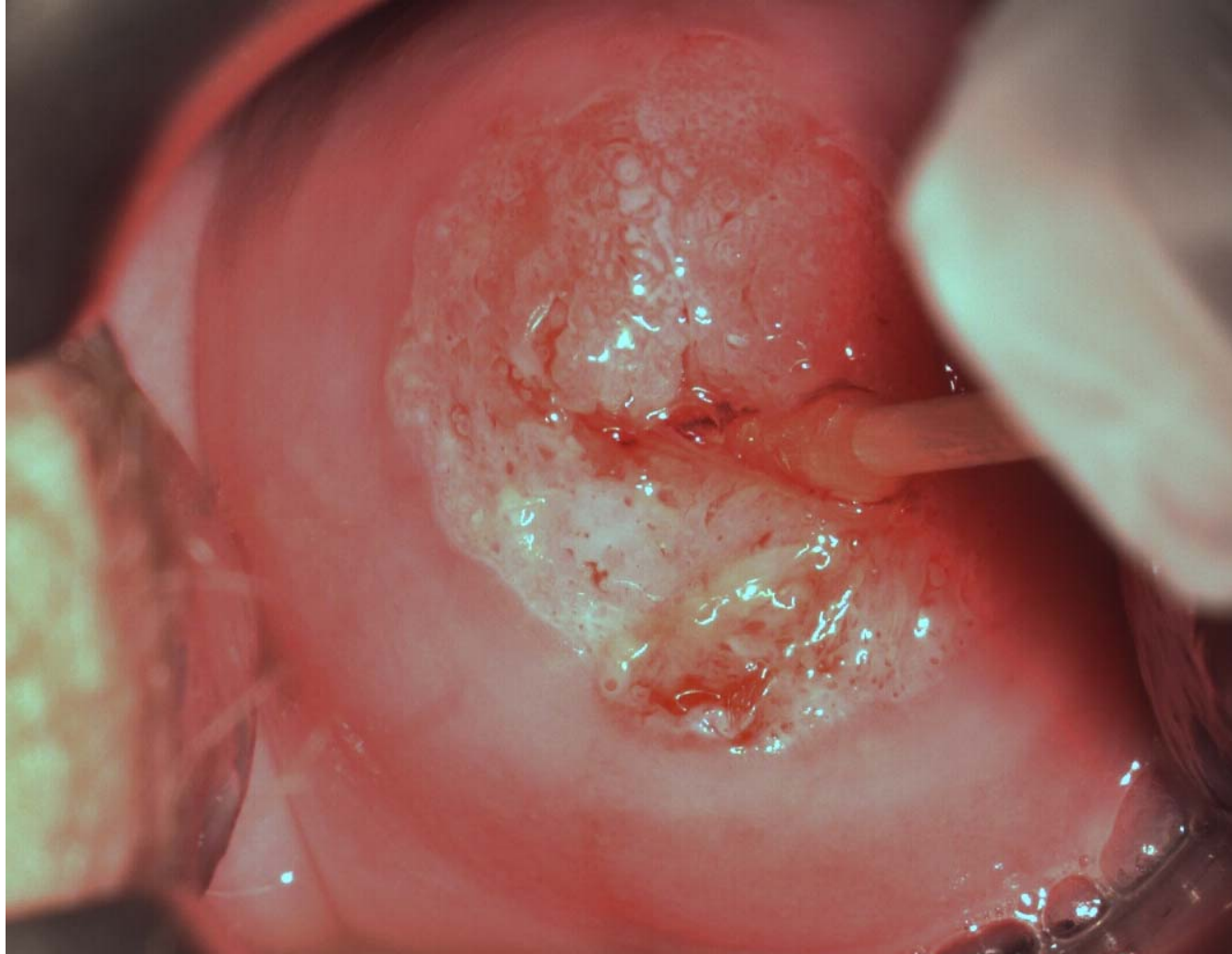
Normale portio?



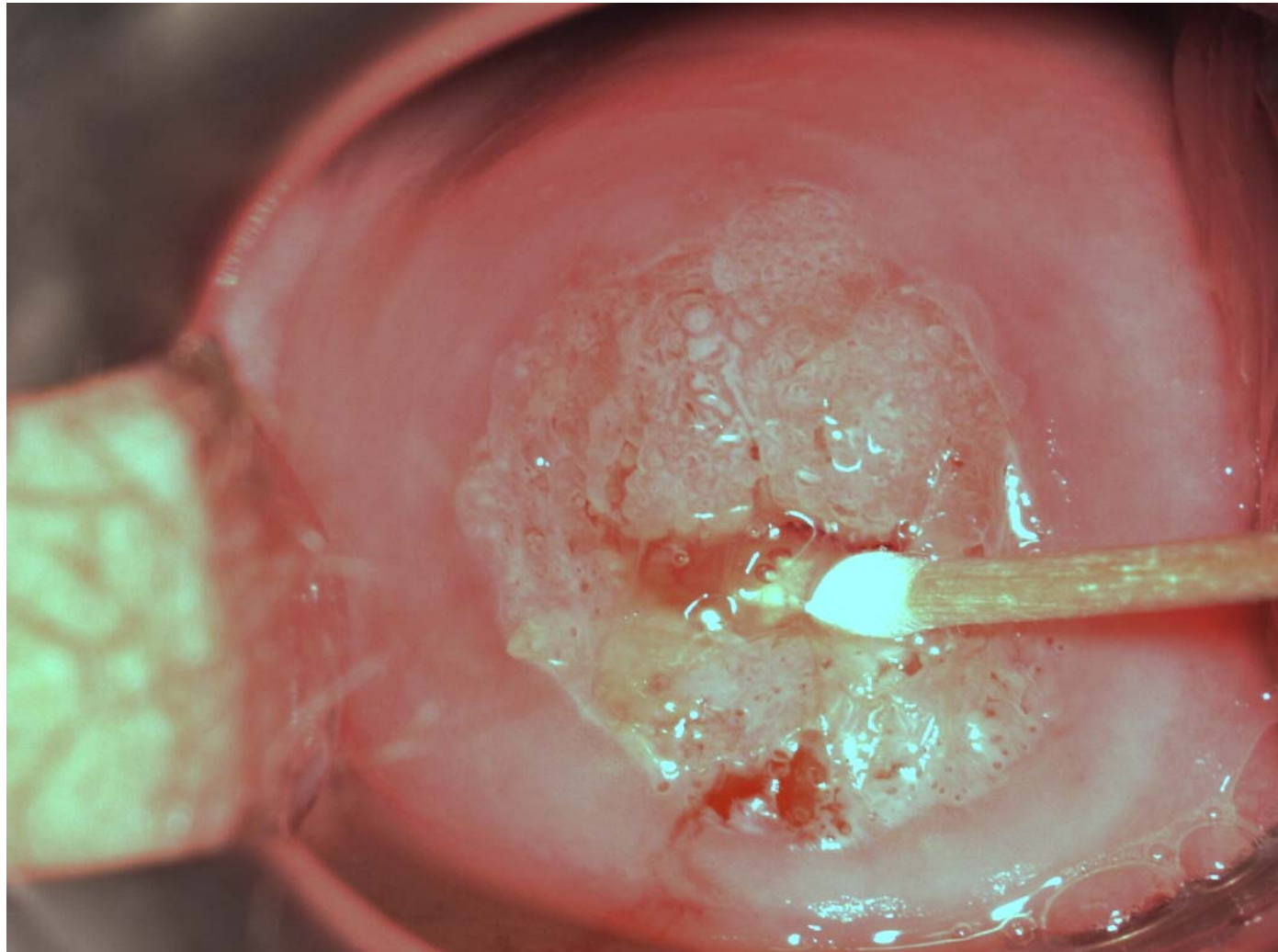
Normale portio?



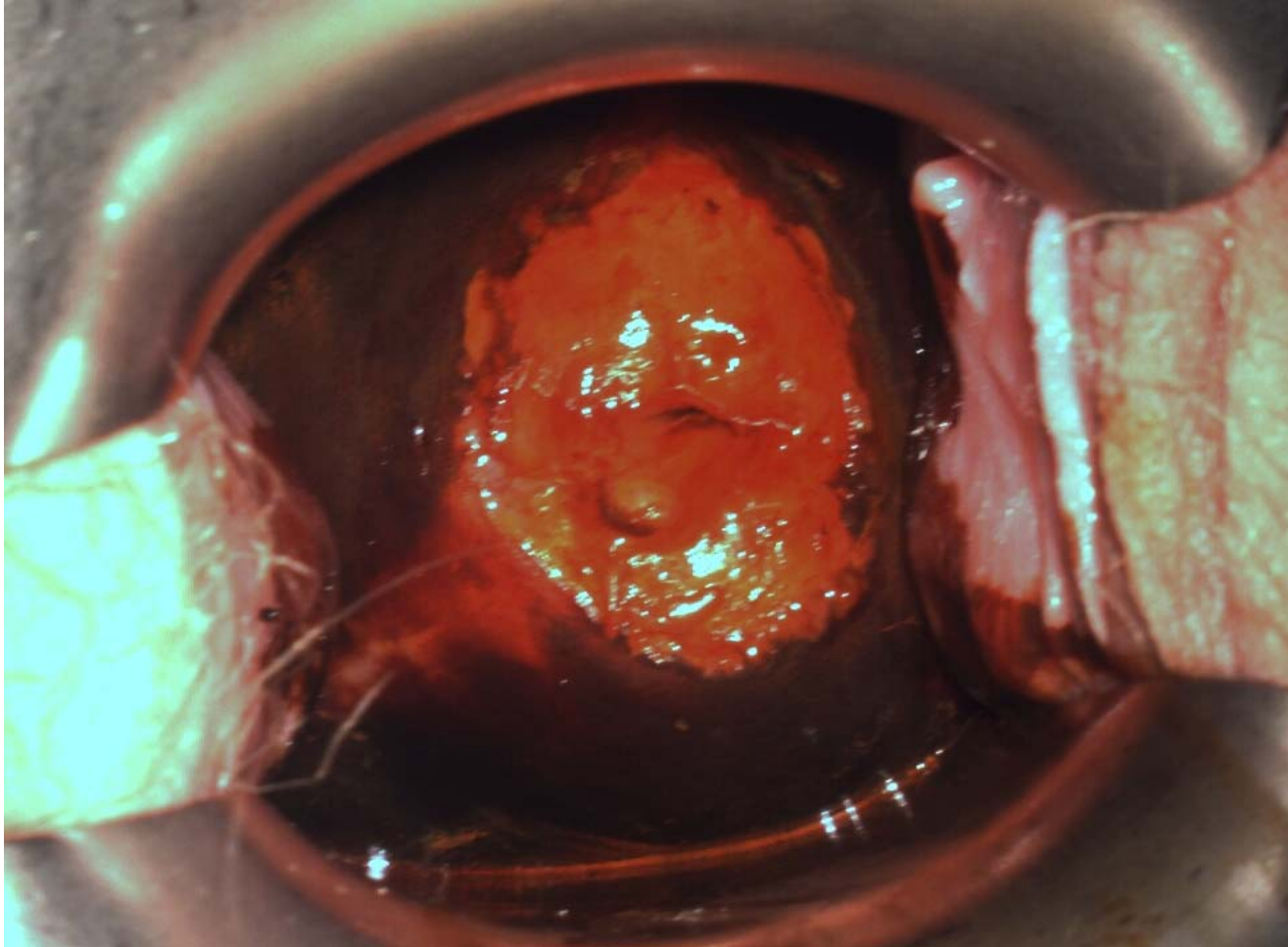
Mozaiek



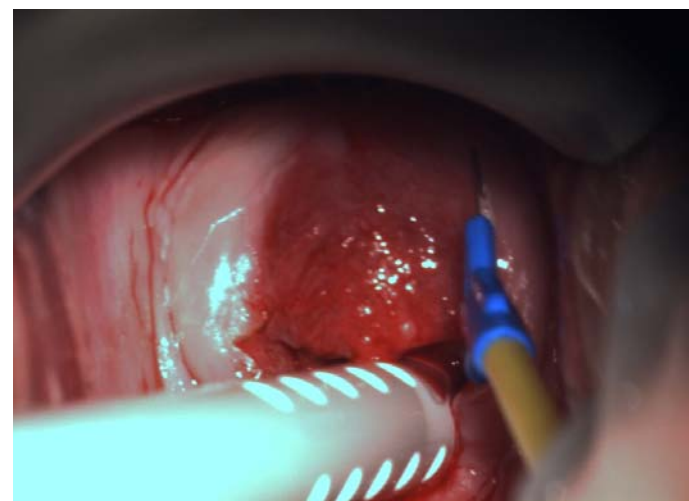
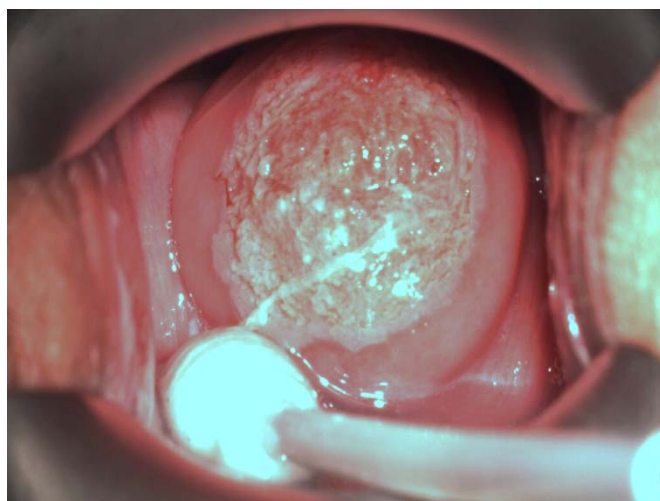
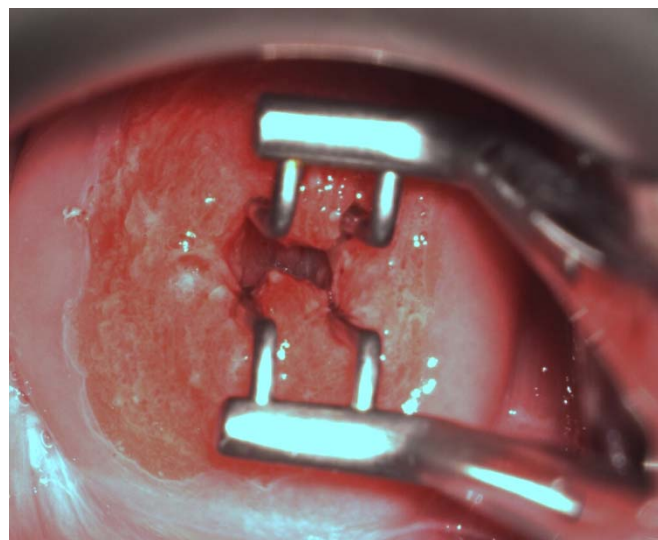
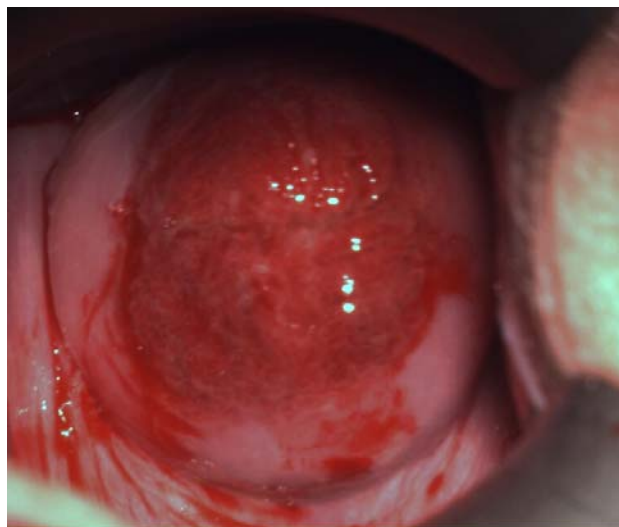
mozaiek



Met lugol



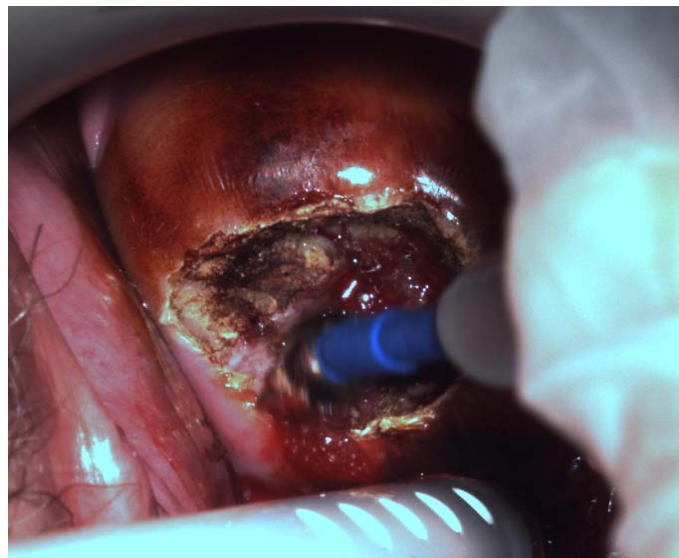
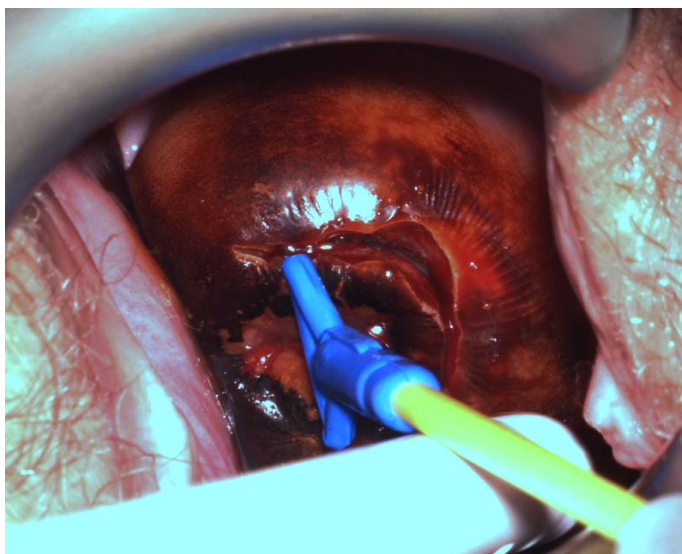
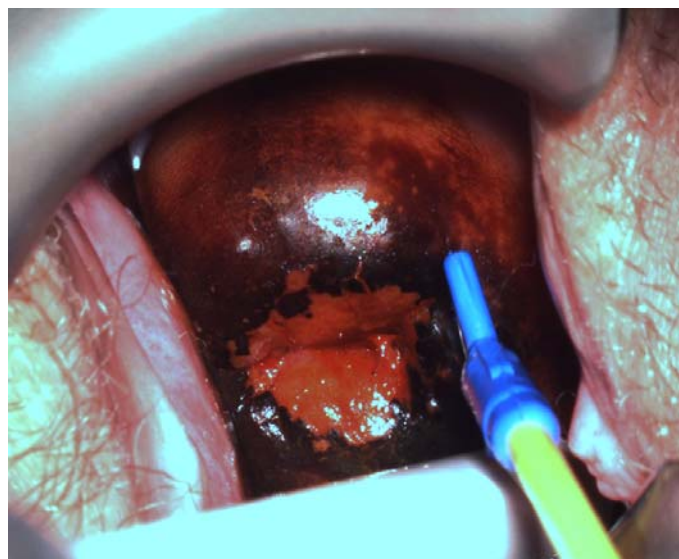
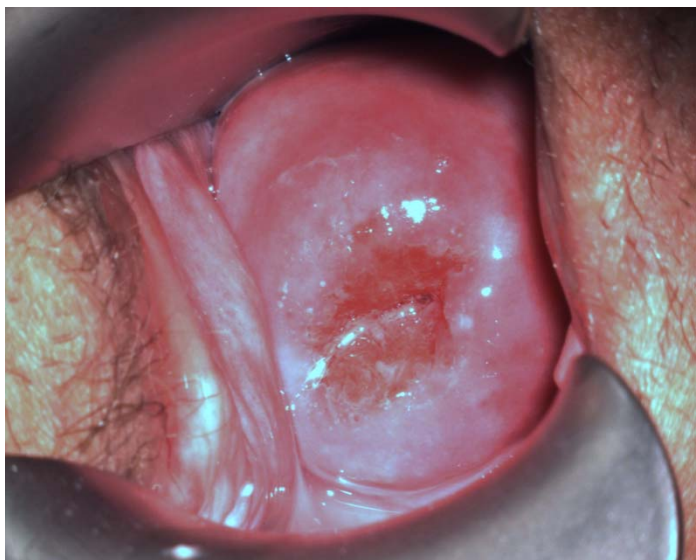ectropion



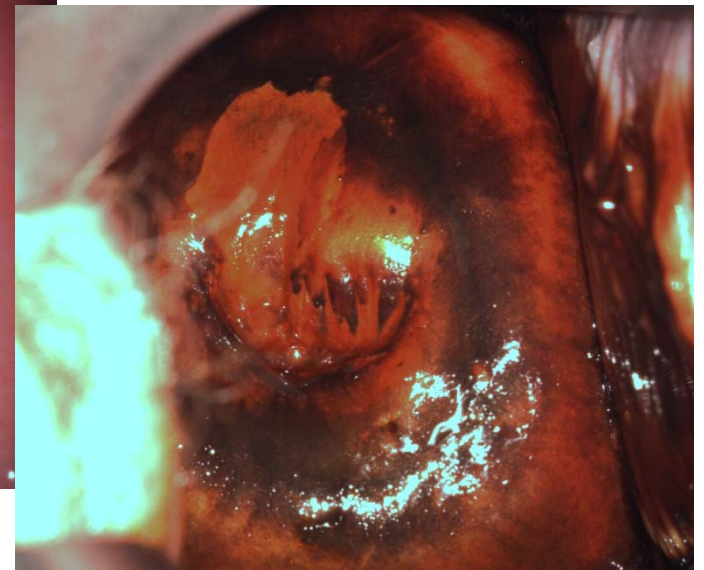
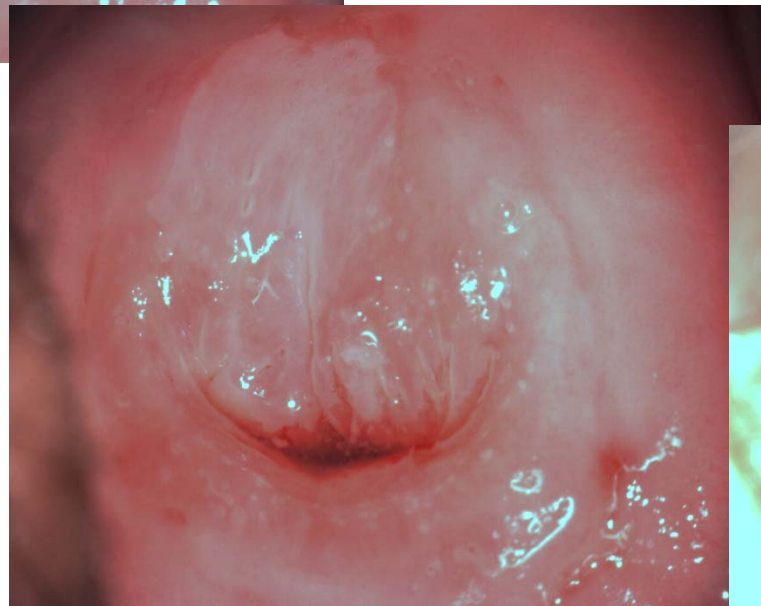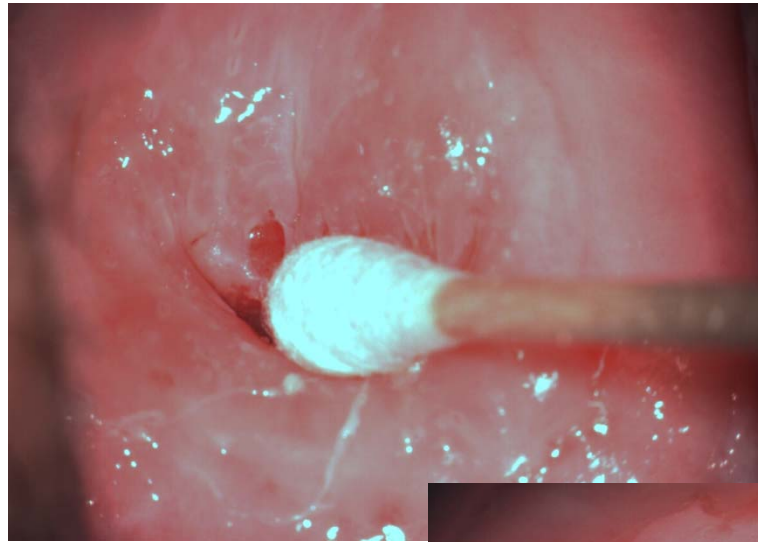
LIS excisie



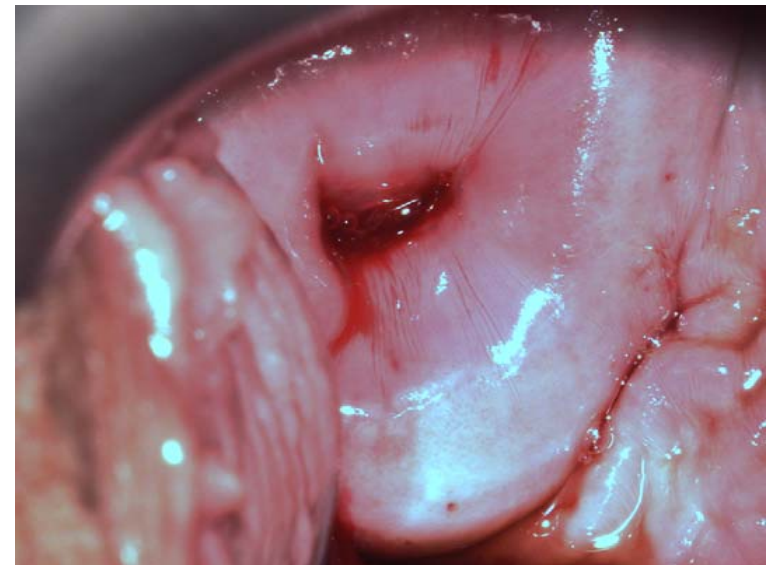
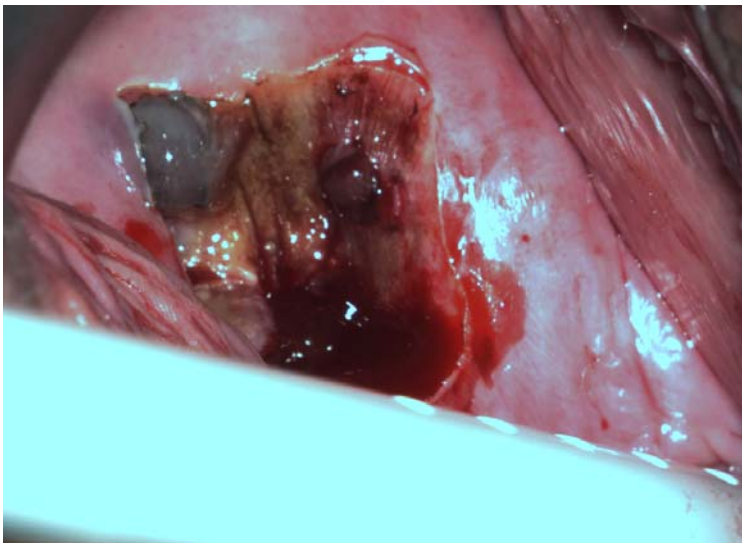
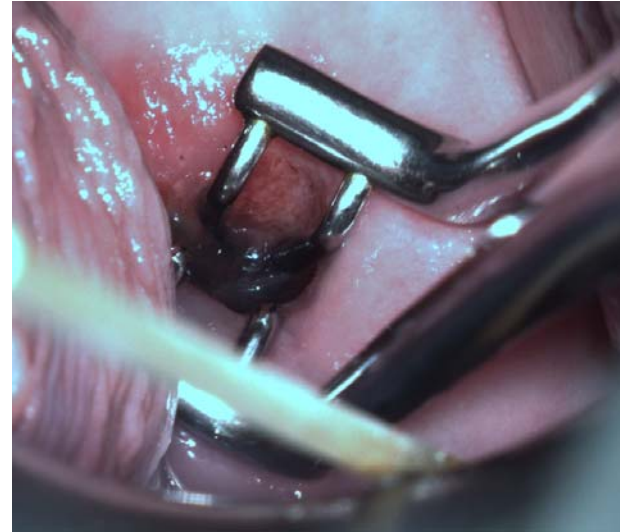
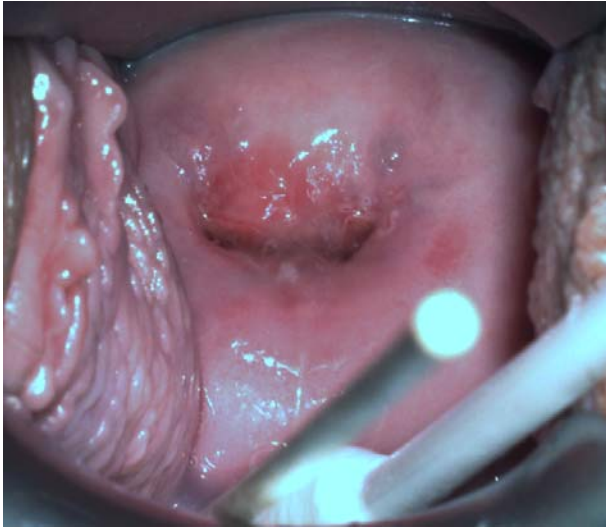
ablatio



Normale portio?



ablatio



Conclusie

- ***Een portio is voor het maken van een uitstrijkje normaal als:***
 - ***De portio in de vagina uitsteekt***
 - ***de opening van het baarmoederhalskanaal daarin te herkennen is***
 - ***en er met het borsteltje van de uitstrijk in een goede cirkelbeweging een uitstrijkje van de hele baarmoedermond te maken is.***

Conclusie

- De cervix is zeer divers in verschijning
- CIN is met blote oog niet te zien